

# Endoscope an essential instrument for every retina surgeon

Cases can benefit from improved visibility with the use of the endoscope.

Ocular Surgery News U.S. Edition, June 10, 2016

*Rupan Trikha, MD*

Optimal visualization of the posterior segment is essential in all forms of retinal and vitreous surgical procedures. It becomes even more important when media opacities degrade the view of the retina and vitreous due to corneal scarring, altered anterior segment with significant scarring, lenticular clouding due to dense cataracts, or the presence of blood from hyphema or vitreous hemorrhage. In these and other situations, the use of an endoscope provides a view of the posterior segment to allow surgical evaluations and procedures to be performed despite these media opacities. Additionally, the endoscope permits visualization of anteriorly located structures, including the ciliary body and the sub-iris space.

Historically, Thorpe first introduced endoscopy in ophthalmology in 1934. In 1978, endoscopy evolved to an instrument with a 13- to 14-gauge shaft, followed by a 20-gauge probe in 1990. Also by 1990, Volkov and colleagues introduced flexible endoscopes. The next step was the use of laser via the endoscope. Currently, a 23-gauge endoscopy probe with laser capability is available for use in various disease states involving the posterior segment of the eye. While the 19.5-gauge probe with a high-resolution camera offers up to 17,000 pixels and 140° of view, the 23-gauge probe drops the resolution to 6,000 pixels with a reduced field of view of 90° and requires a 330 W xenon light source for optimal viewing. Thus, over the last several decades, endoscopy has emerged as a useful technology in vitreoretinal surgery.

Endoscope utility is varied, including endoscopy-assisted vitrectomy, penetrating and perforating ocular injuries, post-traumatic endophthalmitis, intraocular foreign bodies, viewing the posterior segment with media opacities, peripheral panretinal photocoagulation in ischemic retinopathies, proliferative vitreoretinopathy, glaucoma management with endocyclophotocoagulation and other applications. However, the endoscope has a learning curve for the retina surgeon, it does not provide stereopsis and has a limited view with the smaller- gauge probes, and it may be challenging in some cases of membrane peeling.

In this column, Dr. Trikha emphasizes the importance of the endoscope in surgical retinal practice.

Thomas “TJ” John, MD

OSN Surgical Maneuvers Editor



Rupan Trikha

Visualization is the universally challenging aspect of retinal surgery. Good visualization is critical to successful outcomes, and when it is bad, we suffer. Despite well-developed surgical methods and wide-angle viewing devices, the success of retinal surgery ultimately requires a clear media — a relatively clear cornea, lens and vitreous. Although skill and training make it possible to work around less than ideal circumstances, endoscopic technology offers high-resolution views of the posterior segment — an invaluable tool in overcoming the limitation of the operating room microscope.

## **Do I really need an endoscope?**

Emphatically, yes. The endoscope is a unique and important instrument capable of improving visualization in settings in which no other solution is available; every retina surgeon can benefit from incorporating the endoscope during surgery. Use of the endoscope during routine surgery is like a vehicle backup camera. Previously considered a luxury add-on feature, the backup camera is now standard on every newly manufactured car. Obviously, this is not because we absolutely need the camera in order to back our car out of a parking spot, but because the device adds value and improves the overall safety of operating a vehicle. Although we may not rely completely on the backup camera, it affords us a new perspective, and we use it simply because it is there. In fact, once we use it, it becomes challenging to work without it. Likewise, you may currently not have to depend on an endoscope for your surgical cases, but once you have become proficient with it, it becomes indispensable.

Microendoscopy that incorporates video imaging, wide-field illumination and laser has recently become available in a variety of sizes (18 gauge to 25 gauge), resolutions and viewing angles. This has allowed me to use it in every case.

## **What is the learning curve?**

The key to successfully using the endoscope is to learn during the simple, routine cases rather than waiting until faced with a situation in which imaging is an absolute necessity in order to perform the surgery. Start by using the device in scenarios in which you could easily work without it. For instance, it has been advised to learn to use B-scan ultrasonography on easy cases in which visibility in the eye is clear. This allows us to understand what we are looking at and what is normal, and then identify abnormalities. Without gaining experience on the easy cases, we simply would not understand what we are looking at in the difficult cases. Like the B-scan, the endoscope is a supplemental tool, and it does take some time to learn to use it. Once mastered, the visibility it provides makes us better at what we do.

Just like anything in life, the trick is to practice, practice, practice. Manipulated much like a light pipe, I suggest starting with a 20-gauge endoscope. This affords an excellent wide-angle view and bright illumination. The tradeoff, of course, is a 20-gauge incision that requires suturing. However, once you reach a level of comfort, then you can gradually step up to a smaller gauge endoscope. Begin by looking in the eye and learning how to orient the device correctly. It is important at this stage to develop a technique to securely handle the device so that it is second nature to use the scope during complex cases. I would say that most surgeons will become comfortable using the endoscope after three to five cases.

## What is different about endoscopic imagery?

The endoscope offers a unique perspective to traditional wide-angle views, which provide views similar to “overhead lighting.” In comparison, the endoscope acts like the flashlight beam in a dark room. The bright image allows for focus on a specific area and a look under obstructions. For example, in the event of a dense vitreous hemorrhage, I can use the endoscope to go right up to the retina and confirm that it is flat. With the endoscope, the visibility requirement is nominal at 1 mm as compared with the operating microscope, which requires good visibility of the entire eye in order to view the retina.

## What cases would I use the endoscope for?

Every single case can benefit from the endoscope. Begin with routine cases in which you have clear visibility so that you can learn correct orientation and position of the endoscope within the eye. Pseudophakic patients are preferred for initial cases, but this is not critical. As with learning any new technology, use it often and in cases in which it is not essential. This will allow you to be prepared for cases in which it is the only visualization method. This strategy was best exemplified in my early experience with endophthalmitis vitrectomy cases. In my first year with the endoscope, I found it to be minimally helpful in a case of

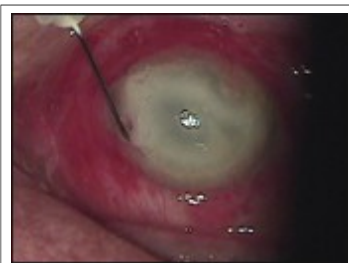

Figure 1. Endophthalmitis with an opacified cornea.

*Images: Trikha R.*

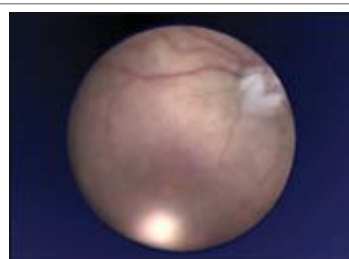


Figure 2. View through the endoscope in a patient with an opacified cornea after vitrectomy.

endophthalmitis. As I gained more experience, I realized the true potential of this technology. I was later able to perform a very thorough vitrectomy and even repair retinal detachments in these difficult cases, all using the endoscope. Had I only used the endoscope for complex cases in which there was media opacity, my skill level would not have improved, and I would have simply blamed the technology for being limited rather than my inexperience.

As I have become more skilled in using the endoscope, I have progressed to using it for more delicate anterior segment procedures. The endoscope permits direct visualization behind the iris, a location that is difficult to access even with aggressive scleral depression. One common situation I use the endoscope for is to remove retained lens fragments from the anterior vitreous. I can quickly turn, without assistance, and look anteriorly to examine the entire vitreous base for retained lens fragments.

Although atypical, a particularly difficult case involved one haptic of a three-piece lens becoming lodged underneath the iris. During this case, haptic externalization was being performed for sutureless scleral fixation. Instead of further manipulating the lens, I was able to locate the haptic with the endoscope, where it was trapped underneath the iris, and externalize it easily.

Interestingly, an opacified cornea or keratoprosthesis, the obvious reason for the use of the endoscope, is quite rare for our practice. We actually find it very helpful in our routine cases. Additionally, endoscopy has also allowed me to expand the scope of my practice in terms of managing multiple diseases simultaneously. Retinal diseases and their treatments are often associated with glaucoma. I now have the ability to simultaneously treat surgical retinal diseases and glaucoma during routine or complex vitrectomy cases.

## **Conclusion**

Endoscopy is a necessity to the retina surgeon, offering a solution to the problem of poor visibility. Conquering the learning curve on routine cases will help surgeons be comfortable in using the endoscope during difficult procedures and in expanding the breadth of treatment options offered.

### **References:**

Ben-nun J. *Ophthalmology*. 2001;doi:10.1016/S0161-6420(01)00642-X. de

Smet MD, et al. *Eye (Lond)*. 2008;doi:10.1038/sj.eye.6702710.

Norris JL, et al. *Am J Ophthalmol*. 1978;doi:10.1016/S0002-9394(14)77741-4.

Thorpe HE. *Trans Am Acad Ophthalmol Otolaryngol*. 1934;39:422-24.

Uram M. *Ophthalmic Surg Las Imag*. 1995;doi:10.3928/1542-8877-19950701-17.

Zhang J, et al. *Eur J Ophthalmol*. 2015;doi:10.5301/ejo.5000606.

### **For more information:**

Rupan Trikha, MD, can be reached at Monmouth Retinal Consultants, 39 Sycamore Ave., Little Silver, NJ 07739; email: [rtmedicine@gmail.com](mailto:rtmedicine@gmail.com).

Edited by Thomas "TJ" John, MD, a clinical associate professor at Loyola University at Chicago and in private practice in Oak Brook, Tinley Park and Oak Lawn, Ill. He can be reached at email: [tjcornea@gmail.com](mailto:tjcornea@gmail.com).